

Use of a bioartificial dermal regeneration template for skin restoration in combat casualty injuries

Military personnel who survive combat injuries frequently have large soft tissue wounds complicated by concomitant injuries and contamination. These devastating wounds present a therapeutic challenge to not only restore the protective skin barrier but also to preserve tendon and muscle excursion, provide protective padding around nerves and restore adequate joint motion. Accordingly, regenerative medicine modalities that can accomplish these goals are of great interest. The use of bioartificial dermal regeneration templates (DRT), such as Integra DRT (Integra Lifesciences Corporation, Plainsboro, NJ, USA), in the management of complex soft tissue injuries has an important role in the reconstruction of war wounds. These DRTs provide initial wound coverage and help establish a well-vascularized wound bed suitable for definitive soft tissue coverage.

First draft submitted: 27 May 2015; **Accepted for publication:** 3 November 2015; **Published online:** 18 December 2015

Keywords: amputation • bioartificial dermal regeneration template • bioartificial dermal substitute • engineered dermis • integra • polytrauma wound management • soft tissue coverage

Blast-related exposures have caused the majority of battlefield injuries during the conflicts in Iraq and Afghanistan [1]. The explosive devices employed by enemy forces have ranged from large, commercially produced artillery and tank ordinance to small, homemade devices derived from ammonium nitrate fertilizer and other makeshift chemicals/materials (improvised explosive devices [IEDs]). These weapons produce a diverse spectrum of blunt, penetrating and thermal injuries depending on the ordinance yield, placement, construction and victim armoring or personal protective gear [2]. Wounds produced from explosive blasts generally have extensive zone of injuries with multiple anatomical sites of involvement. They often involve composite-type injuries (i.e., have concomitant bone and associated soft tissue involvement) and are highly contaminated [2–4].

Due to innovations such as improved vehicle armoring, better personal protective body equipment as well as deployment of surgical teams ever closer to the point of battlefield injury, a higher proportion of combat-injured personnel are surviving than in any previous war [1]. The complexity of war wounds requires reconstructive surgeons to employ a variety of techniques to optimize reconstructive outcomes, often employing all aspects of the reconstructive ladder in combination with regenerative medicine therapies. Bioartificial dermal regeneration templates (DRT) have shown promise in augmenting traditional soft tissue reconstructive techniques in their ability to provide a vascularized soft tissue bed and/or in creating a ‘neodermis’ or dermal regenerate [5]. These products are typically composed of sheets of acellular collagen with or without a semipermeable outer layer to control heat and/or moisture loss.

Jonathan G Seavey¹, Zachary A Masters², George C Balazs¹, Scott M Tittle^{1,2}, Jennifer Sabino³, Mark E Fleming^{1,2} & Ian L Valerio^{*,2,4}

¹Department of Orthopaedic Surgery, Walter Reed National Military Medical Center, 8901 Wisconsin Ave., Bethesda, MD 20889, USA

²Uniformed Services University of the Health Sciences, 4301 Jones Bridge Road, Bethesda, MD 20814, USA

³Department of General Surgery, Walter Reed National Military Medical Center, 8901 Wisconsin Ave., Bethesda, MD 20889, USA

⁴Department of Plastic Surgery, The Ohio State University Wexner Medical Center, 915 Olentangy River Road, Ste 2100, Columbus, OH 43212, USA

*Author for correspondence:

Tel.: +1 614-403-9815

ian.valerio@osumc.edu

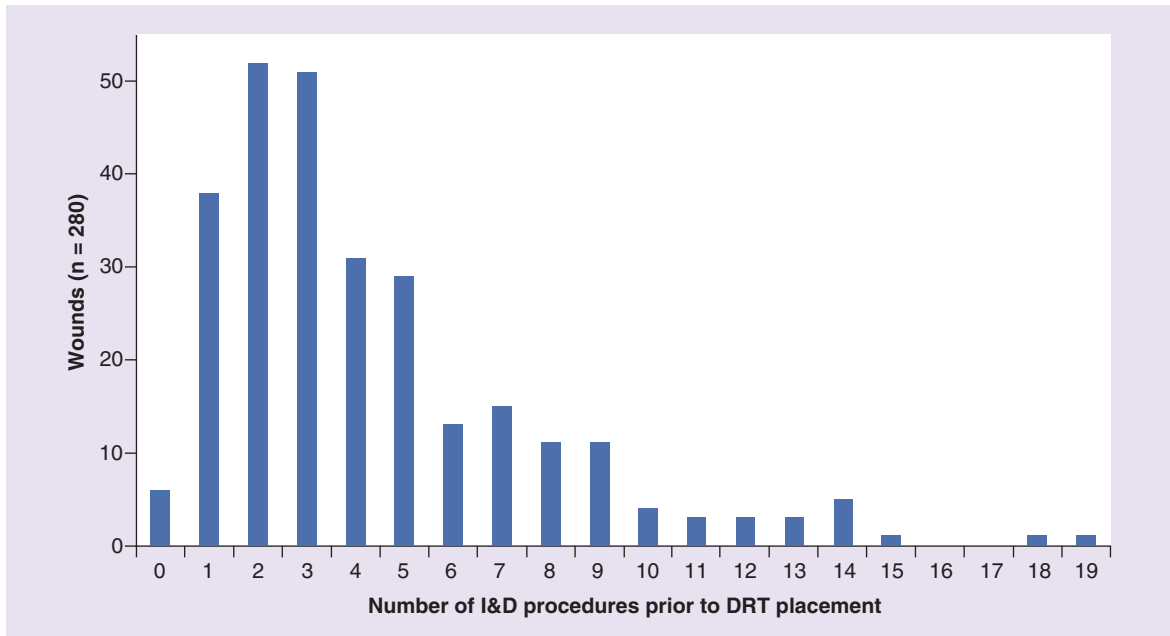


Figure 1. Number of irrigation and debridement procedures after arrival and prior to bioartificial dermal regeneration template grafting procedure.

DRT: Dermal regeneration template; I&D: Irrigation and debridement.

When placed on a full thickness wound, a specific sequence of cellular invasion and graft incorporation occurs; resulting in formation of a vascularized dermal regenerate, or ‘neodermis’ that may be skin grafted or allowed to heal by secondary intention [6,7]. The use of negative pressure wound therapy (NPWT) over

the DRT has been shown to facilitate neovascularization [8,9] as well as decrease bacterial colonization [10] and has been utilized in our practice for treating combat wounds [11].

While described extensively in the treatment of burns, fewer reports exist on the use of DRT in trauma

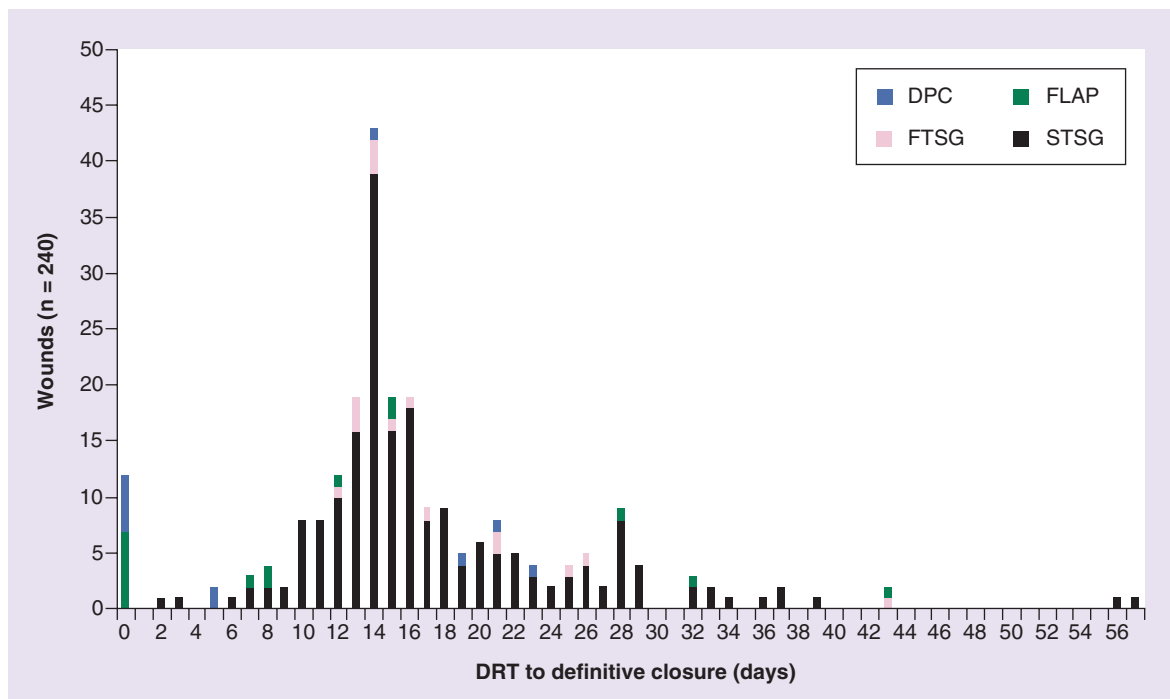


Figure 2. Days from bioartificial dermal regeneration template grafting to definitive closure.

DRT: Dermal regeneration template; DPC: Delayed primary closure; FLAP: Wound coverage with a vascularized flap; FTSG: Full-thickness skin graft; STSG: Split-thickness skin graft.

Table 1. Chronology of wound treatment.

Anatomical Site	Injury to arrival (days)	Arrival to DRT (days)	I&D procedures (days)	DRT to DC (days)	Injury to DC (days)
Upper extremities	5 (2–38)	8 (1–66)	3 (0–14)	14 (0–57)	34 (11–82)
Lower extremities	5 (2–47)	8 (1–53)	3 (0–19)	15 (0–37)	35 (9–101)
Nonextremity	5 (3–9)	13 (3–59)	8 (1–18)	16 (14–56)	64 (24–105)

Days from injury to arrival at our facility, days from arrival to bioartificial dermal regeneration template grafting procedure (DRG), number of I&D procedures after arrival and prior to DRG, days from DRG to DC, days from injury to DC. All values are given as median (range).
DC: Definitive closure; DRT: Dermal regeneration template; I&D: Irrigation and debridement.

care or combat casualty care. These regenerative modalities have several potential benefits in the treatment of such wounds, including: coverage of exposed tendons, nerves, blood vessels and/or bone; decreasing or eliminating the need for more morbid procedures such as tissue transfers; promotion of a well-vascularized bed in at-risk or hypovascular wounds; lessening the need for shortening of amputated extremities by providing more stable soft tissue coverage and durability and contouring of soft tissue defects to improve cosmesis, function and/or comfort with prosthetic wear [11,12].

Most previous studies of DRT in the treatment of traumatic wounds are limited to series of mainly civilian trauma. Only two studies have examined the use of DRT in the treatment combat injuries, both involving cohorts of less than 20 patients [11,13]. Our institution has extensively utilized these regenerative products over many years in the treatment of war casualties from Iraq and Afghanistan. The purpose of this study was to describe our experience with the use of a bioartificial DRT in coverage of full thickness traumatic wounds as an adjunct to traditional soft tissue reconstructive procedures.

Patients & methods

Following approval from our Institutional Review Board, we performed a retrospective review of all patients treated with the most common bioartificial DRT used in our practice – Integra DRT (Integra Lifesciences Corporation, NJ, USA) for combat-related traumatic wounds from November 2009 through July 2013. Our computerized surgical scheduling system was searched for all patients during the study period treated with this specific bioartificial DRT, and medical records were screened. Patients were included if they were treated for traumatic wounds sustained during deployment to Operations Iraqi Freedom or Enduring Freedom. Patients were excluded if they were treated for nontraumatic injuries such as diabetic ulcers and necrotizing soft tissue infections.

For each included patient, data were collected on patient demographics, injury circumstances and characteristics, surgical treatment details and final wound outcome. Definitive closure was defined as a treatment after which no further coverage procedures would be expected or necessary and included: split-thickness skin grafting (STSG), full-thickness skin

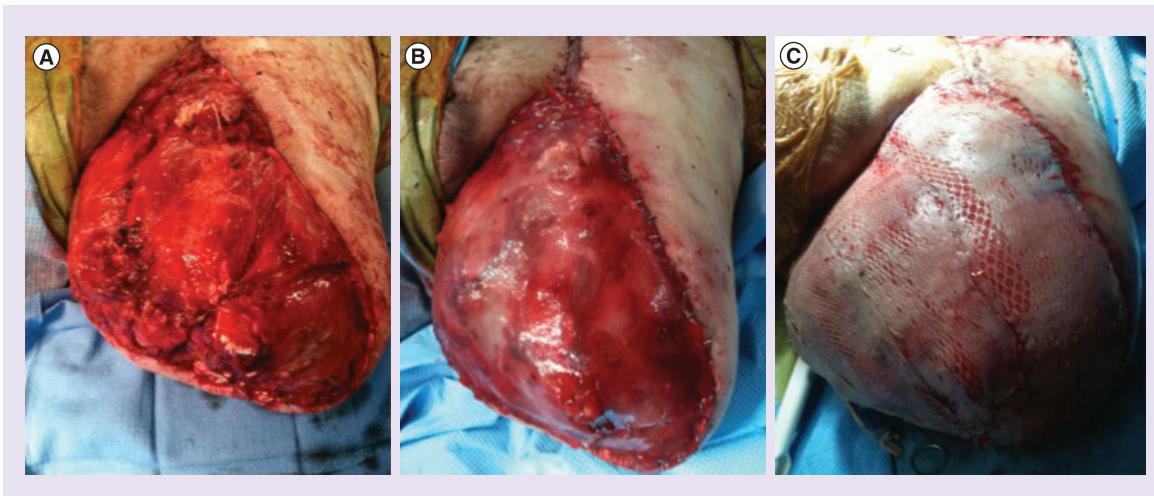


Figure 3. Left lower residual limb Injury and reconstruction. (A) Left lower extremity above knee amputation with significant soft tissue avulsion injury and skin defect. (B) Same injury after placement of dermal regeneration template for residual limb length preservation. (C) Same injury after dermal regeneration template incorporation and application of split-thickness skin grafting salvaging residual limb length and restoring soft tissue/skin defect.

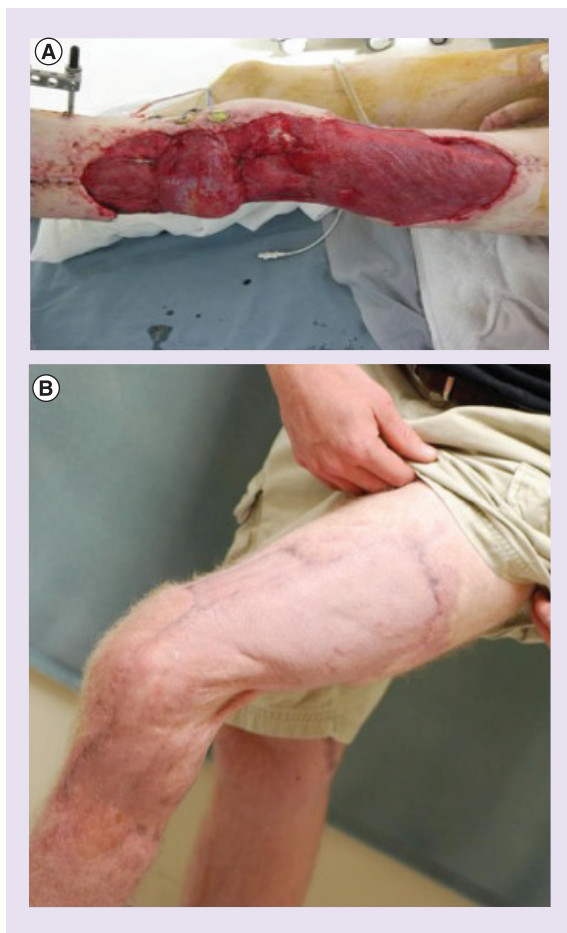

Figure 4. Left lower extremity injury and reconstruction. (A) Left lower extremity wound from blast trauma after lateral gastrocnemius flap for coverage of open knee joint. (B) Salvaged extremity 2 years after hybrid reconstruction with flap, dermal regeneration template and split-thickness skin grafting. Patient has full range of motion of knee and ambulating on successful limb salvage via traditional and regenerative therapies in combination.

grafting (FTSG), flap coverage, delayed primary closure (DPC), amputation of the injured extremity with immediate closure or revision of an existing amputation to a higher level with immediate closure. For purposes of this study, skin grafts and flaps were categorized as either ‘good take’ ($\geq 90\%$ healing) or ‘failed’ ($< 90\%$ healing, requiring additional procedures to achieve definitive coverage). Wounds treated by DPC were considered successful if no record of additional procedures or wound breakdown was found in the medical record. Wounds with incomplete documentation were counted as failures; healing rates for patients with complete records only are also reported separately. Wounds that resulted in amputation or revision of an existing amputation to a more proximal level were uniformly considered treatment failures, even if the reason for amputation was not related to failure of the DRT.

Procedures performed prior to arrival in our facility (e.g., in a combat hospital or en route to a tertiary care facility in the USA) were not included in the analysis due to inconsistent availability of documentation.

The primary outcome of the study was healing of the wound following DRT placement, as measured by successful take or stable definitive coverage with second stage skin grafting, flap procedure or in the cases of DPC, healing of the closed wound. Secondary outcomes measured included number of irrigation and debridement procedures prior to DRT placement, time from arrival to DRT placement, time from DRT placement to definitive closure and overall time from injury to definitive closure.

Results

All patients in our series had undergone primary surgical evaluation and stabilization measures at in-theater military medical treatment facilities in either Iraq or Afghanistan prior to medical evacuation to our stateside medical center in Bethesda, MD, USA. This medical care generally consisted of point of care treatment administered at time of injury by self or other soldiers/marines (‘buddy-aid’) or Navy corpsman/Army medics and consisted of tourniquet and dressing placement, \pm splinting and field treatment of life-threatening injuries until the patient could be transported to the next echelon of care. Wounds were debrided as soon as practicable and then every 24–72 h depending on patient condition and anticipated transport to the next level of care.

Upon arrival at our facility, patients were immediately assessed and typically taken to the operating room the following morning for wound exploration, irrigation and debridement, cultures and other procedures as dictated by the specific pattern of injury. Wound management was at the discretion of the treating surgeon however, wounds were surgically debrided and examined every 48–72 h. We routinely used NPWT over the wounds. The KCI V.A.C. (Kinetic Concepts, Inc., TX, USA) was the most frequently used system. Settings were surgeon dependent, but in general 125 mmHg low-continuous suction was employed.

Placement of an Integra DRT was pursued once the wound beds were deemed stable and healthy; this technique has been previously described [11]. Following DRT placement NPWT was typically used; V.A.C. dressings were changed under anesthesia approximately every 3 days. For wounds (particularly those on the hands/fingers) less amenable to placement of NPWT dressings, sterile dressings were employed. Splints were utilized based on clinical picture to minimize shear stresses. Following incorporation of the DRT, autologous skin grafting was pursued where indicated. NPWT was also frequently utilized following autolo-

gous skin grafting, although this was surgeon and wound dependent. This dressing was typically taken down at 5 days. For wounds closed via DPC, an incisional NPWT dressing set at 75 mmHg was frequently employed to decrease shear stress at the incision site.

A total of 190 patients with 280 wounds were treated with an Integra DRT during the study period (see **Supplementary Table 1** for total patient dataset and outcomes). Mean age was 23.5 years (range: 19–48 years) and 189/190 patients were male. Wounds were most commonly located on the extremities with a small percentage (<10%) on the torso and head and neck. In total, 29 wounds had incomplete documentation: data on method of closure were unavailable for 21 wounds, and on degree of graft-take in an additional eight. All were treated as treatment failures in the analysis.

Among the 251 wounds for which treatment and outcome information was available, there was one death following DRT placement but prior to definitive closure; mortality was not the result of DRT failure or associated wound complication. Two regeneration templates were completely lost due to infection. Of the remaining 248 wounds, 198 (80%) were treated with STSG, 15 (6%) were treated with FTSG, 16 (6%) were covered with a local or free tissue flap, 11 (4%) were treated with DPC and eight (3%) limbs required ampu-

tation or revision of the amputation to a higher level. For the wounds definitively covered with flaps, in eight instances the DRT was used at the time of, or subsequent to, flap placement, frequently to cover flap edges and then typically skin-grafted. In other cases, where the DRT was used prior to flap coverage it was frequently done to cover vital structures and those prone to desiccation, often as a temporizing measure to allow wounds to evolve over multiple debridements, establish hemodynamic stability off pressors and permit overall stabilization of the clinical picture prior to free tissue transfer. In no instances in our series was the decision for flap coverage based on loss of the DRT.

Overall a total of 78% (217/280) of these combat wounds healed after the first attempt at definitive closure following Integra treatment. When wounds with incomplete documentation are excluded, the success rate was 86% (217/251).

The median time from injury to arrival was 5 days (range: 2–47 days). Patients underwent a median of three irrigation and debridement procedures (range: 0–19 procedures) prior to DRT placement over a median of 8 days (range: 1–66 days) (see **Figure 1**). Overall, the median time from DRT placement to definitive closure (STSG and FTSG, DPC and flap coverage) was 15 days (range: 0–57 days). The median

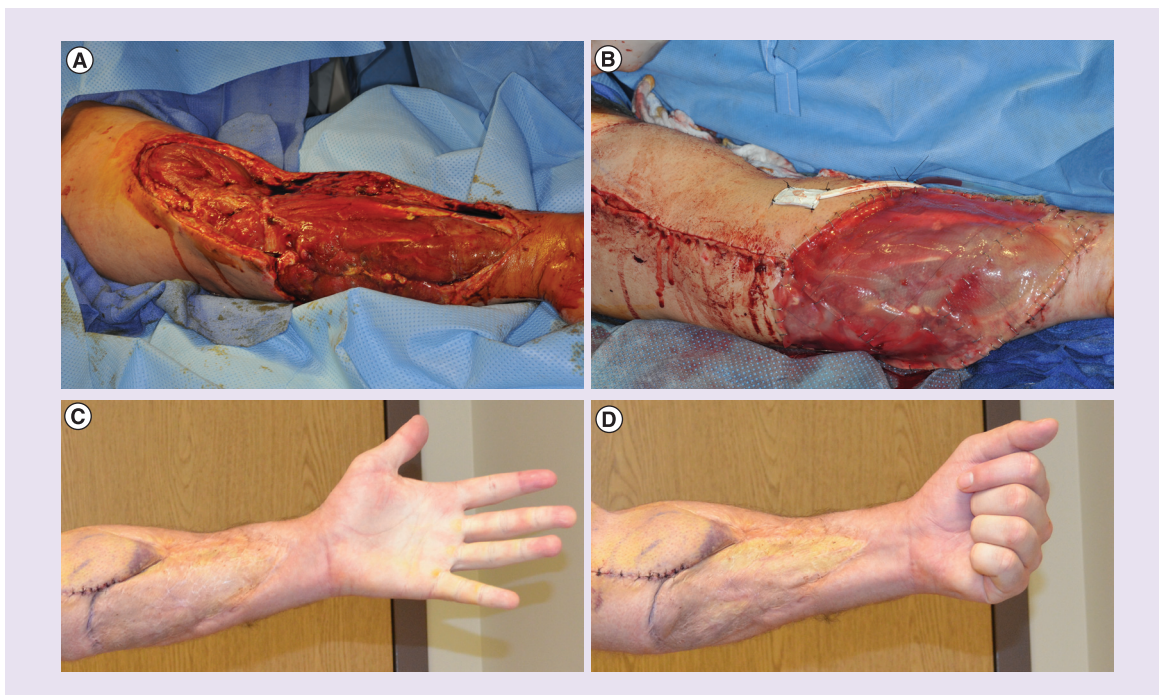


Figure 5. Left upper extremity and reconstruction. (A) Left upper extremity injury with complex soft tissue injury and fractures from blast-related exposure. (B) Same injury after free flap transfer and dermal regeneration template to complete first stage reconstruction and prior to split-thickness skin grafting placement. (C) Reconstructed extremity 2 years after hybrid reconstruction with flap, dermal regeneration template and split-thickness skin grafting showing ability to extend upper extremity. (D) Same extremity showing ability to perform flexion of salvaged upper extremity.

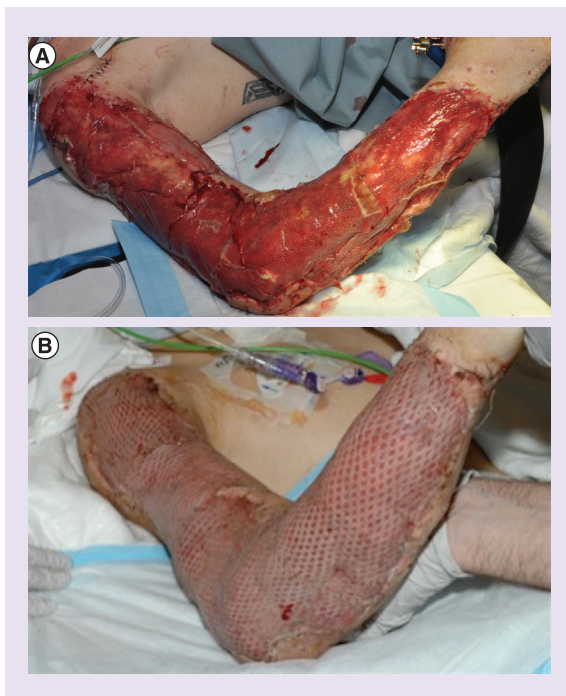

Figure 6. Right upper extremity injury and reconstruction. (A) Right upper extremity injury with complex soft tissue injury and fractures from blast-related exposure after dermal regeneration template placement. (B) Salvaged extremity after dermal regeneration template and split-thickness skin grafting placement showing early results. Patient has nearly full use of this arm, can perform pull-ups and push-ups with this extremity illustrating functional capacity and range of motion.

time from injury to definitive closure was 35 days (range: 9–105 days) (see Figure 2 & Table 1).

Discussion

There are multiple different varieties of bioartificial DRTs and substitutes available, but this series includes only patients treated with an Integra DRT, as this product has been the most commonly utilized at our institution (see Figures 3–6 for example cases). Integra DRT is a porous matrix of cross-linked bovine tendon collagen and shark glycosaminoglycan (chondroitin-6-sulfate) integrated with a semipermeable polysiloxane (silicone) layer [14]. The bilaminar structure of this DRT is well suited for large-area and wound applications such as those frequently encountered with blast wounds and high-velocity ballistic projectiles. In addition to providing an inner layer of regenerative scaffold that facilitates migration and in-growth of fibroblasts, macrophages, lymphocytes and capillaries and enables formation of a vascularized neodermis for second stage skin grafting or other soft tissue coverage options, the temporary outer layer of semipermeable silicone serves as an artificial epidermis which may protect

from infection and helps to regulate moisture and heat loss/retention [5,14].

In the burn and trauma literature, bioartificial DRTs have been used for reconstruction of large complex wounds, degloving injuries and wounds with exposed bone, tendon, nerve or vascular structures (with and without accompanying peritenon, periosteum, perineurium or perivascular structures). In matched case–control series of 88 patients (44 each group), Jeng *et al.* report their 7 years of experience using DRT to manage complex soft tissue wounds, often with significant volume loss and threatened extremities as the result of tendon, joint or bone exposure. They utilized these DRT for coverage of fourth-degree burns, necrotizing fasciitis, pit-viper envenomations and total abdominal wall avulsion injuries. Soft tissue defects were filled using serial DRT applications to restore surface contours or for coverage over exposed tendons, bones and joints. In their series Integra DRT allowed for the unexpected salvage of several threatened extremities and significantly decreased the amputation rate from 31.5% in the control group to 5.7% in the treatment group [12].

A case series of seven pediatric patients highlighted the use of Integra DRT and NPWT in grade IIIB tibia fractures – in all cases the soft tissue healed without need for flap or amputation. Complications included two superficial graft complications and one nonunion [15]. In another series, use of Integra DRT followed by autologous skin grafting allowed complete graft take and excellent functional results in nine of 10 patients who sustained traumatic degloving injuries to an extremity [16]. In a series of 15 patients with traumatic mixed upper and lower extremity full-thickness injuries, use of a dermal substitute enabled healing in all cases: six of 15 required a second application of the dermal substitute, and five patients required skin grafting to complete healing. Infection was reported in one case [17].

DRTs have been successfully used despite bacterial colonization and local ischemia in various reports. Muangman *et al.* reported a series of 29 burn patients, with a mean wound size of 43% total body surface area. In their cohort, 90% of wounds showed bacterial growth on quantitative cultures, with 31% demonstrating $>10^5$ colony-forming units. Despite this, successful take of the DRT occurred in 83%, with successful delayed skin grafting in 92% of these wounds. Among highly colonized wounds, they reported successful takes of 78 and 86% for the DRT and second stage autograft, respectively [18].

More recently, Michot *et al.* reported the use of DRT over exposed vascular structures following femorotibial arterial bypass surgery with uneventful healing of the wound. They hypothesized that DRT may

be less demanding in terms of the vascular wound bed and the degree of oxygenation than a conventional skin graft [19].

Combat injuries share many characteristics with the injuries described in the preceding studies as they are often traumatic degloving injuries, with associated open fractures, heavy contamination, often with large zones of injury and concomitant tissue ischemia due to vascular injury and tourniquet use [20–22]. Despite this, there are few reports of DRT use in combat trauma and military populations. We were only able to identify two series in the surgical literature. Helgeson *et al.*, reported a case series of 16 complex blast wounds with exposed bone and/or tendon treated with DRT and negative-pressure wound therapy followed by skin grafting; successful definitive coverage was achieved in 15 of 16 wounds [11]. In the UK, Foong *et al.* reported on the use of DRT in the treat-

ment of IED blast injuries in seven patients – applications included both upper and lower extremities as well as amputated limbs, with successful closure of all wounds by delayed skin grafting following DRT placement [13]. Our substantially larger series validates these earlier findings, demonstrating the excellent results that can be obtained with this adjunctive treatment: we achieved a rate 78% successful initial closure of 280 wounds following DRT placement; this rate increases to 86% if wounds with incomplete data are excluded, which is consistent with previously reported results (see Figures 3–7 for case examples and flowsheet of treated wounds).

There are several important limitations to this study. As a retrospective series it relies on existing records and suffers from the usual biases and incomplete data of any record review. While we were able to identify 280 wounds in 190 patients, complete data were only

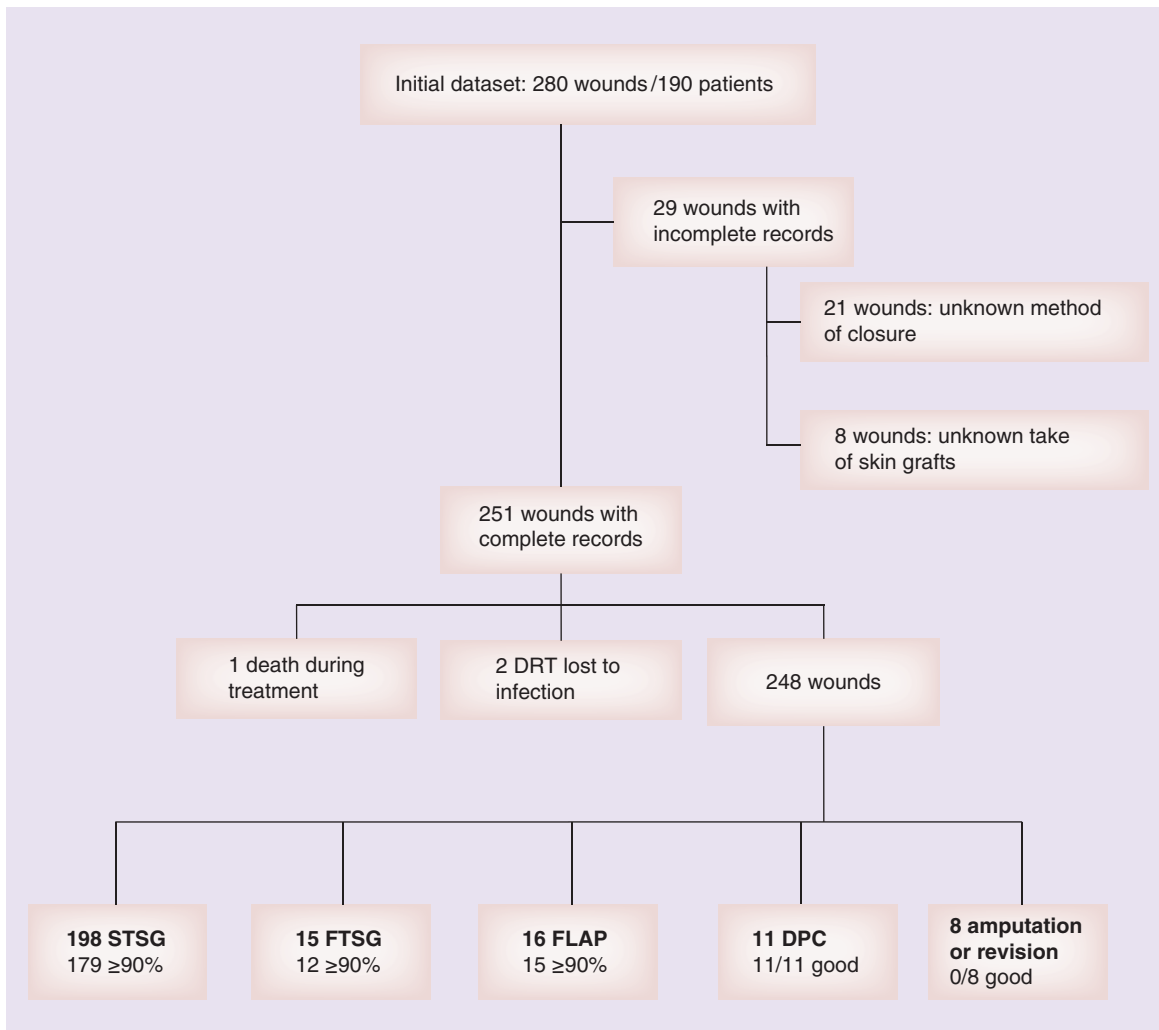


Figure 7. Flowsheet outlining outcomes of 280 wounds in the 190 patient series.

DPC: Delayed primary closure; DRT: Dermal regeneration template; FTSG: Full-thickness skin graft; STSG: Split-thickness skin graft.

available for 251. There were 29 records with incomplete data or 10% of the total dataset. Further, the search method utilized only captured patients where the search terms were included in the surgical booking system. There may be instances where an Integra DRT was utilized, but was not included in the surgical booking system: these patients would not have been included in our dataset.

Assessment of the 'take' of both skin grafts and tissue flaps was performed by multiple treating surgeons and residents; accordingly, there may be discrepancies between observers. We attempted to mitigate this by categorizing take in a binary manner and setting 90% take as the low-cutoff for the 'good' grouping. In truth, many of the wounds with 70–90% take healed with bedside measures and local wound care (no further operative procedures), however for the purposes of this study, due to take of less than 90%, they were considered treatment failures. We reported two cases of complete regeneration template loss; however, partial loss is difficult to calculate as a result of the same interobserver variability described above and limited documentation in the electronic medical record. However, we found no cases where possible partial loss contributed to wound closure failure or failed reconstruction, so partial loss of a DRT is likely of limited clinical significance.

Despite these limitations, we feel we have demonstrated a substantial benefit to utilizing a bioartificial regeneration template such as Integra DRT in augmenting traditional soft tissue reconstructive procedures for combat-injured patients. Some of the strengths of this study are that it is the largest series of traumatic wounds treated with bioartificial DRT to date, and the healing rate reported is all the more impressive given that these were primarily blast wounds with heavy contamination at time of injury. Although in our population, IED blast injuries are typically confined to active duty service members, this is not the case at other institutions and we believe that the results of this study are applicable to similar civilian injuries.

Conclusion

Bioartificial DRTs such as Integra DRT have played an increasing role in the treatment of traumatic war wounds having significant skin defects. Utilizing the beneficial structural aspects of these materials, our reconstructive surgeons have successfully achieved stable, closed wounds despite many of these wounds having been complicated by significant infectious burden, hypo- or avascular tissue, as well as full-thickness skin defects with exposed vital structures. The use of DRTs for skin restoration have been shown to aid in the functional properties of skin

via the DRTs' ability to re-create a well vascularized neodermis that can accept definitive second stage and even primary stage epidermal coverage. Furthermore, application of DRTs permit the reconstitution of the skin's inherent barrier functions, aids in a 'cushoning effect' in protecting the underlying anatomical structures in which it covers, while also permits adequate glide and motion functions of the underlying tendons and muscle units. However, long-term functional outcomes are still pending and further investigation is necessary to truly evaluate the utility of these products beyond combat casualty care and correlate their use with civilian traumatic and oncologic reconstructions. DRTs have a significant role in not only the treatment of burn and combat related wounds, but also in civilian trauma and a variety of nontrauma applications.

Future perspective

As further research and clinical experiences is gained within DRTs and skin substitutes, the potential for restorative techniques to improve the functional and aesthetic aspects of cutaneous and soft tissue wounds will be transformative to reconstructive, burn, and wound care. Such future work will lead to better options for addressing cutaneous, soft tissue, and composite type defects, will aid in improving patient clinical outcomes, and will likely be integral components in applications to other tissue replacement areas and via novel tissue engineering approaches. Next steps will include combining DRTs and skin substitutes with cellular therapies to further improve and recapitulate the functional aspects of skin and its contents such as hair bearing elements, sebaceous glands, and sensory organelles which will more realistically replicate the anatomical components of skin. Current DRTs and substitutes available clinically lack the ability to restore these specialty functions of skin and primarily serve as a dermal regenerate or replacement rather than a fully functioning skin replacement.

Supplementary data

To view the supplementary data that accompany this paper please visit the journal website at: <http://www.futuremedicine.com/doi/full/10.2217/rme.15.83>.

Acknowledgements

The authors would like to thank the Departments of Orthopaedic and Plastic and Reconstructive Surgery at Walter Reed National Military Medical Center for their support of this work.

Disclaimer

The views expressed in this presentation are those of the authors and do not necessarily reflect the official policy or posi-

tion of the Department of the Army, Department of Defense, nor the US Government.

No writing assistance was utilized in the production of this manuscript.

Financial & competing interests disclosure

The authors have no relevant affiliations or financial involvement with any organization or entity with a financial interest in or financial conflict with the subject matter or materials discussed in the manuscript. This includes employment, consultancies, honoraria, stock ownership or options, expert testimony, grants or patents received or pending, or royalties.

Ethical conduct of research

The authors state that they have obtained appropriate institutional review board approval or have followed the principles outlined in the Declaration of Helsinki for all human or animal experimental investigations. In addition, for investigations involving human subjects, informed consent has been obtained from the participants involved.

Executive summary

- War wounds are often complex composite defects devoid of well-vascularized tissue in critically ill patients. These injuries require serial surgical debridements to remove necrotic, contaminated and compromised tissue.
- Bioartificial dermal regeneration templates (DRTs) are typically composed of bovine, porcine, ovine or human collagen matrix which facilitates vascularization and formation of a neodermis.
- Bioartificial DRTs utilized in conjunction with traditional soft tissue coverage techniques play a role in the reconstruction of combat wounds.
- Integra DRT can provide wound stabilization, via a temporary mechanical barrier that lessens evaporative losses and help to achieve definitive staged wound closure.
- In our series Integra DRT had an 86% success rate in the treatment of traumatic injuries, even in highly contaminated wounds with large zones of injury.
- Use of Integra DRT may decrease the need for flap procedures or repeat autologous skin grafting.
- Future prospective studies are needed to compare the use Integra DRT to traditional soft tissue procedures and to elucidate the potential costs or savings associated with its use.

References

- 1 Hoencamp R, Vermetten E, Tan EC, Putter H, Leenen LP, Hamming JF. Systematic review of the prevalence and characteristics of battle casualties from NATO coalition forces in Iraq and Afghanistan. *Injury* 45(7), 1028–1034 (2014).
- 2 Ramasamy A, Hill AM, Clasper JC. Improvised explosive devices: pathophysiology, injury profiles and current medical management. *J. R. Army Med. Corps* 155(4), 265–272 (2009).
- 3 Champion HR, Holcomb JB, Young LA. Injuries from explosions: physics, biophysics, pathology, and required research focus. *J. Trauma* 66(5), 1468–1477 (2009).
- 4 Eskridge SL, Macera CA, Galarneau MR *et al.* Injuries from combat explosions in Iraq: injury type, location, and severity. *Injury* 43(10), 1678–1682 (2012).
- 5 Burke JF, Yannas IV, Quinby WC, Jr., Bondoc CC, Jung WK. Successful use of a physiologically acceptable artificial skin in the treatment of extensive burn injury. *Ann. Surg.* 194(4), 413–428 (1981).
- 6 Greenwood J, Amjadi M, Dearman B, Mackie I. Real-time demonstration of split skin graft inosculation and integra dermal matrix neovascularization using confocal laser scanning microscopy. *Eplasty* 9, e33 (2009).
- 7 Moiemens NS, Vlachou E, Staiano JJ, Thaw Y, Frame JD. Reconstructive surgery with Integra dermal regeneration template: histologic study, clinical evaluation, and current practice. *Plast. Reconstr. Surg.* 117(Suppl. 7), S160–S174 (2006).
- 8 Baldwin C, Potter M, Clayton E, Irvine L, Dye J. Topical negative pressure stimulates endothelial migration and proliferation: a suggested mechanism for improved integration of Integra. *Ann. Plast. Surg.* 62(1), 92–96 (2009).
- 9 Molnar JA, Defranzo AJ, Hadaegh A, Morykwas MJ, Shen P, Argenta LC. Acceleration of Integra incorporation in complex tissue defects with subatmospheric pressure. *Plast. Reconstr. Surg.* 113(5), 1339–1346 (2004).
- 10 Lalliss SJ, Stinner DJ, Waterman SM, Branstetter JG, Masini BD, Wenke JC. Negative pressure wound therapy reduces pseudomonas wound contamination more than *Staphylococcus aureus*. *J. Orthop. Trauma* 24(9), 598–602 (2010).
- 11 Helgeson MD, Potter BK, Evans KN, Shawen SB. Bioartificial dermal substitute: a preliminary report on its use for the management of complex combat-related soft tissue wounds. *J. Orthop. Trauma* 21(6), 394–399 (2007).
- 12 Jeng JC, Fidler PE, Sokolich JC *et al.* Seven years' experience with Integra as a reconstructive tool. *J. Burn Care Res.* 28(1), 120–126 (2007).
- 13 Foong DP, Evriviades D, Jeffery SL. Integra permits early durable coverage of improvised explosive device (IED) amputation stumps. *J. Plast. Reconstr. Aesthet. Surg.* 66(12), 1717–1724 (2013).
- 14 Yannas IV, Burke JF. Design of an artificial skin. I. Basic design principles. *J. Biomed. Mater. Res.* 14(1), 65–81 (1980).
- 15 Barnett TM, Shilt JS. Use of vacuum-assisted closure and a dermal regeneration template as an alternative to flap reconstruction in pediatric grade IIIB open lower-extremity injuries. *Am. J. Orthop. (Belle Mead NJ)* 38(6), 301–305 (2009).
- 16 Graham GP, Helmer SD, Haan JM, Khandelwal A. The use of Integra® dermal regeneration template in the

- reconstruction of traumatic degloving injuries. *J. Burn Care Res.* 34(2), 261–266 (2013).
- 17 Vaienti L, Marchesi A, Palitta G, Gazzola R, Parodi PC, Leone F. Limb trauma: the use of an advanced wound care device in the treatment of full-thickness wounds. *Strategies Trauma Limb Reconstr.* 8(2), 111–115 (2013).
- 18 Muangman P, Deubner H, Honari S *et al.* Correlation of clinical outcome of integra application with microbiologic and pathological biopsies. *J. Trauma* 61(5), 1212–1217 (2006).
- 19 Michot A, Chaput B, Gobel F, Menez T, De Bonnecaze G, Pelissier P. Chronic ischaemia does not appear to hinder healing with integra: implementation at a tibial artery bypass site. *Int. Wound J.* doi:10.1111/iwj.12408 (2015) (Epub ahead of print).
- 20 Centeno JA, Rogers DA, Van Der Voet GB *et al.* Embedded fragments from U.S. military personnel—chemical analysis and potential health implications. *Int. J. Environ. Res. Public Health* 11(2), 1261–1278 (2014).
- 21 Clasper JC, Brown KV, Hill P. Limb complications following pre-hospital tourniquet use. *J. R. Army Med. Corps* 155(3), 200–202 (2009).
- 22 Forsberg JA, Pepek JM, Wagner S *et al.* Heterotopic ossification in high-energy wartime extremity injuries: prevalence and risk factors. *J. Bone Joint Surg. Am.* 91(5), 1084–1091 (2009).